

# Spine defect affects one in ten

At least one in ten of the population may have *spina bifida occulta*, a hidden spine or neural tube defect in which vertebrae fail to form properly. It is often not diagnosed until a checkup for an unrelated problem in early adulthood and doctors often do not inform the patient as effects are rarely severe. This can ignore serious implications for people planning to have children

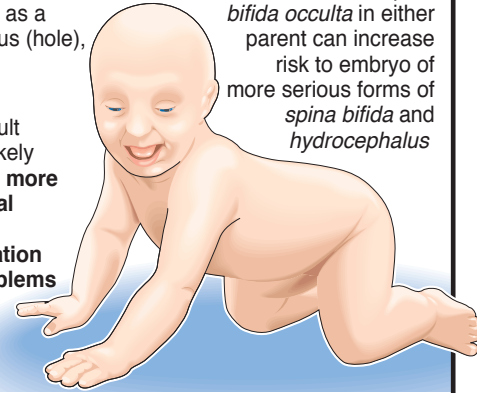
## Spina bifida occulta

**(Hidden split spine)** Easily identified in adult by visible signs such as a mole, birth mark, dimple, sinus (hole), or a patch of hair positioned along ridge of spine

**Commonest form:** Small fault involving one vertebra – unlikely to cause any effects. **Two or more vertebrae involved or spinal cord becomes tethered to backbone** – reduced sensation and weakness in legs, problems with co-ordination and hand control, bladder and bowel problems

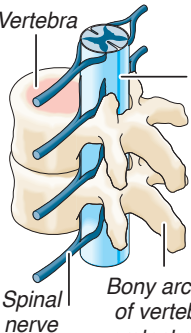
## Risk to babies

Presence of *spina bifida occulta* in either parent can increase risk to embryo of more serious forms of *spina bifida* and *hydrocephalus*



## Spinal column

The spine consists of 33 bones, or vertebrae, which protect the spinal cord – the communication system for the body – and provide anchorage for muscles. The spine and spinal cord develop between the 14th and 25th day after conception



Spinal cord in protective sheath (the meninges)

Bony arches of vertebra protect cord

**1 Cervical spine:** 7 vertebrae Nerves control neck, shoulders and arms

**2 Thoracic spine:** 12 vertebrae Coordinate hands and fingers, chest, abdomen, lower back and hips

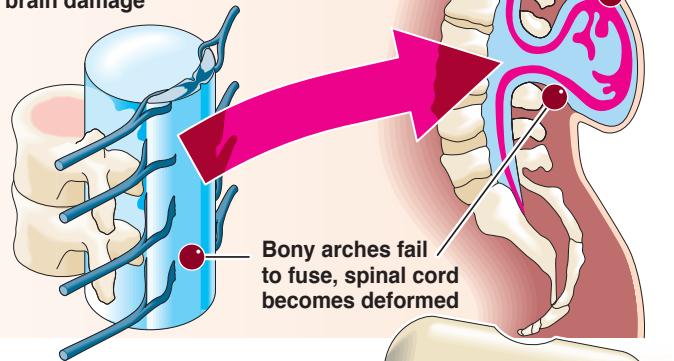
**3 Lumbar spine:** 5 vertebrae Control legs and feet, seat muscles for stability, ejaculation in men

**4 Sacrum:** 5 fused bones Bowels, bladder, erection

**5 Coccyx:** 4 fused vertebrae

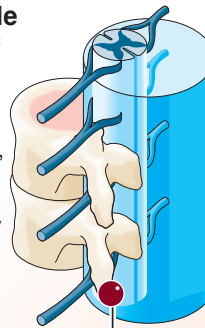
## Myelomeningocele

Most common and most serious form. **Malformation of spinal cord results in severe handicap, including paralysis and brain damage**

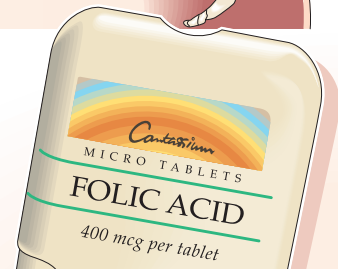

## Meningocele

Rarest form of spina bifida. If nerve tissue of spinal cord remains intact, surgery may repair defect and there may be no serious handicap



Bony arches fail to fuse but spinal cord is undamaged



**Folic acid** (vitamin M, folacin)

Taking a folic acid supplement for at least one month prior to conception and during the first 12 weeks of pregnancy can prevent neural tube defects in up to 72% of 'at risk' pregnancies